

ANTERIOR CERVICAL CORPECTOMY

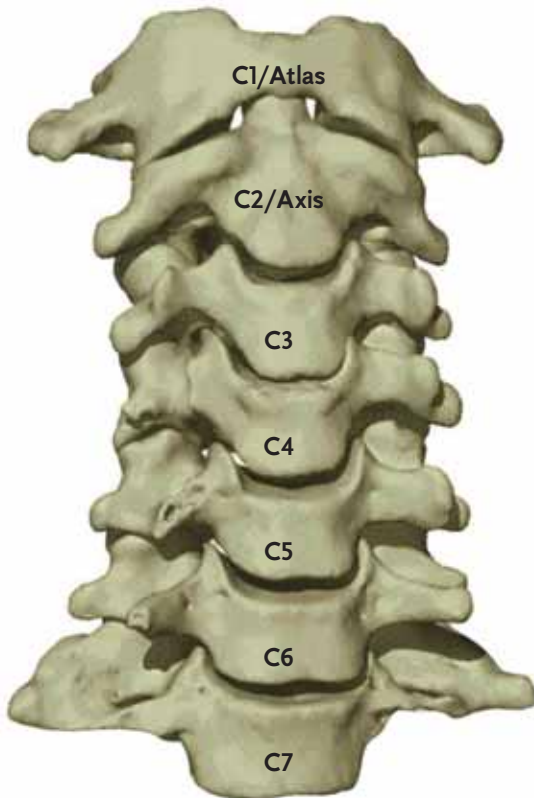
Anterior – In the human anatomy, referring to the front surface of the body or position of one structure relative to another

Cervical – Relating to the neck, in the spine relating to the first seven vertebrae

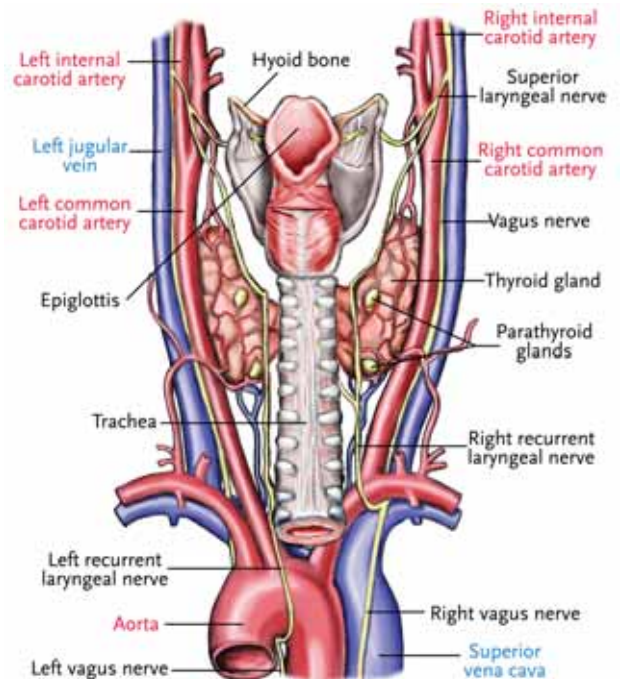
Corpectomy – Removal of the vertebral body as well as the disc spaces at either end, to completely decompress the cervical canal

Basic Anatomical Landmarks: Anterior Cervical Spine

Anterior View
Bone Structure of the Cervical Spine
(C1/Atlas-C7)



Anterior Anatomy
Covering the Cervical Spine

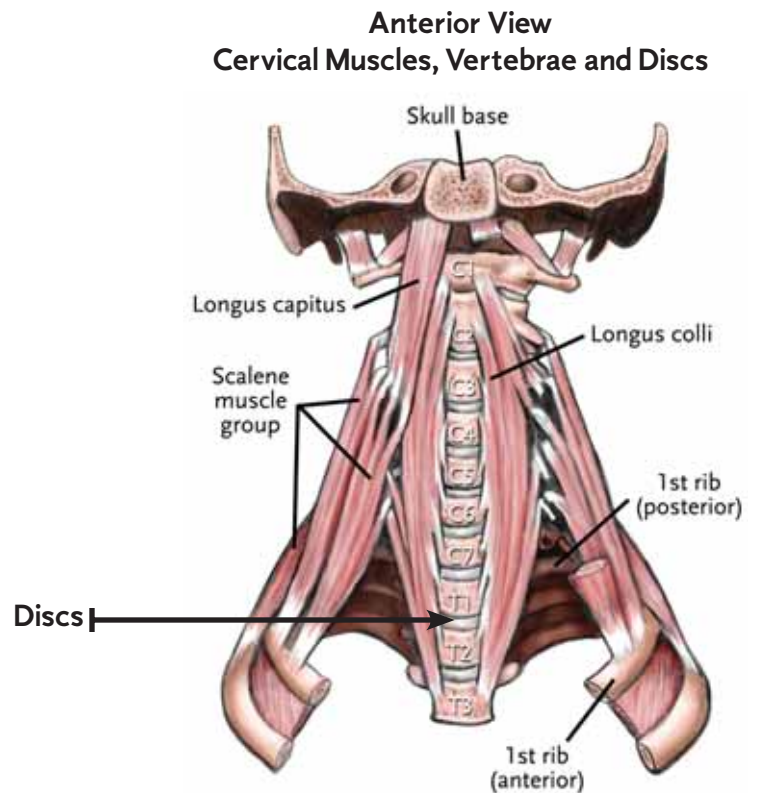


ANTERIOR CERVICAL CORPECTOMY

Basic Anatomical Landmarks: Anterior Cervical Spine

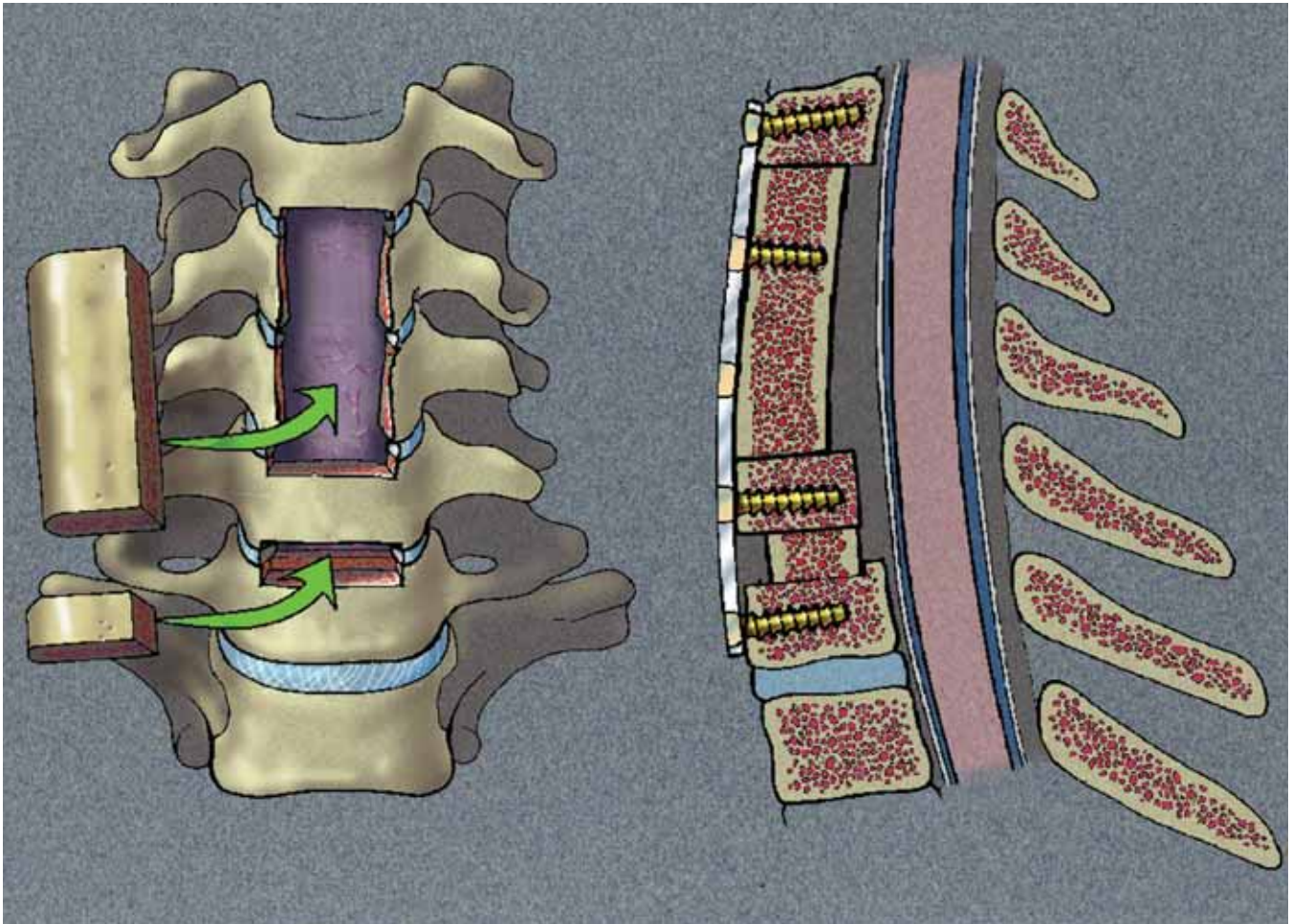
Cervical Discs

In the cervical spine there are intervertebral discs from C2-C7. There is no disc between C1 and C2. In the illustration, the **Discs** appear as the white substance between each vertebrae.



ANTERIOR CERVICAL CORPECTOMY

Approach/Patient Position

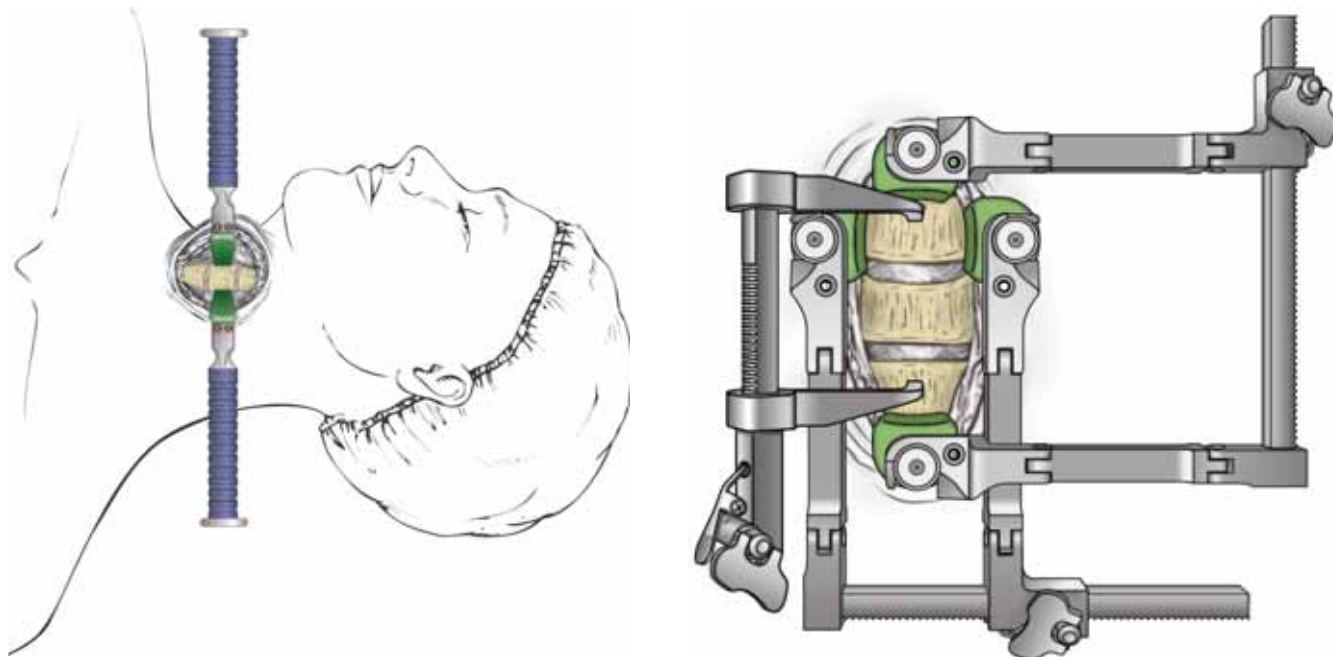


ANTERIOR CERVICAL CORPECTOMY

Approach/Patient Position

The patient is placed in the supine position with the head in slight extension. The surgeon must then choose a right or left sided approach, usually through the left. The laryngeal nerve that controls the voice box runs on the right side of the neck, so the incision is usually left sided to avoid post-op speech problems. After choosing an operative side, the head may be rotated to allow for adequate exposure of the cervical spine.

A skin incision is made and an avascular dissection plane is developed between the esophagus/trachea, medially, and the sternocleidomastoid/carotid sheath, laterally. Hand held retractors might be utilized to provide initial exposure of the anterior vertebral column and the adjacent longus colli muscles.



ANTERIOR CERVICAL CORPECTOMY

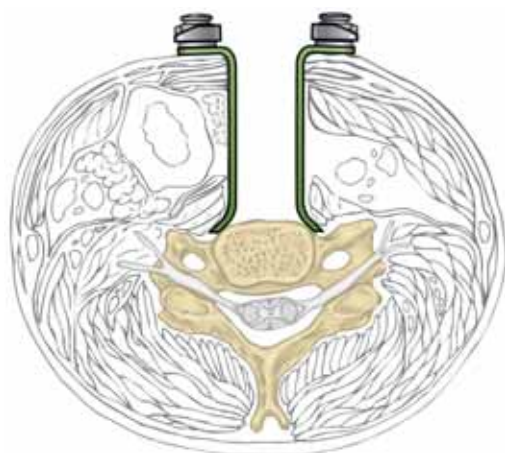
Technique: Corpectomy

The general procedure is as follows:

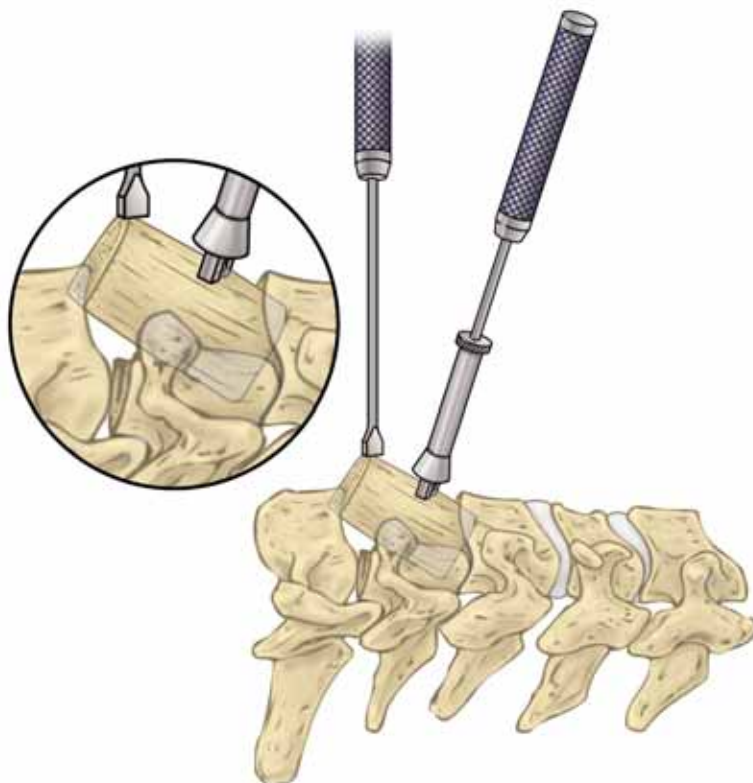
- The approach is similar to a discectomy (anterior approach), although a more vertical incision in the neck will often be used to allow more extensive exposure.
- The surgeon then performs a discectomy at either end of the vertebral body that will be removed (e.g. C4-C5 and C5-C6 to remove the C5 vertebral body). More than one vertebral body may be removed.
- The posterior longitudinal ligament is then removed to allow access to the cervical canal.

This procedure allows the canal to be completely decompressed.

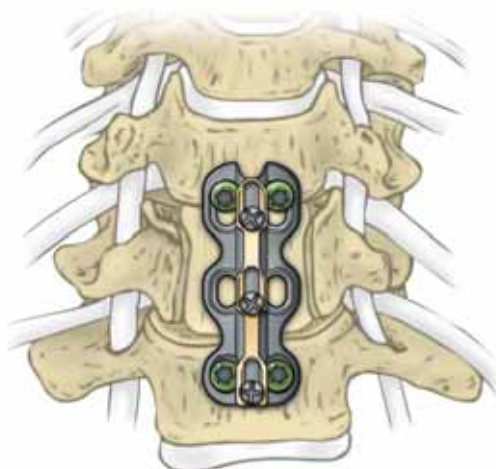
Retraction of Anterior Structures



Corpectomy Providing Complete Decompression



Corpectomy with Anterior Plate



ANTERIOR CERVICAL CORPECTOMY

Technique: Cervical Plating

"Anterior cervical internal fixation is increasingly utilized in spinal surgery. The application of an anterior cervical plate has become widely accepted when anterior spinal fusion is performed to stabilize the spine for tumor, trauma, deformity, degenerative disc disease and other forms of cervical instability. The addition of anterior plate fixation offers many benefits such as: resistance to graft displacement, a reduced incidence of pseudarthrosis related to micro motion at the graft-vertebral body interface, maintaining anterior cervical alignment when multi-level discectomies or corpectomies are performed, and a decreased reliance on prolonged external bracing." (ATLANTIS® Anterior Cervical Plate Surgical Technique as described by: Dr. Volker Sonntag, Dr. Regis Haid, and Dr. Stephen Papadopoulos)

A variety of plate designs currently exist to stabilize the cervical spine and promote fusion. The available options for cervical plating are listed below.

Non-constrained – Bicortical non-locked bone screw

Semi-constrained – Locked bone screw with possible construct motion

Constrained – Locked bone screw with no construct motion

Rotational Load Sharing – Screw rotates about a pivot point

Translational Load Sharing – Screw translates along a slot in the plate

